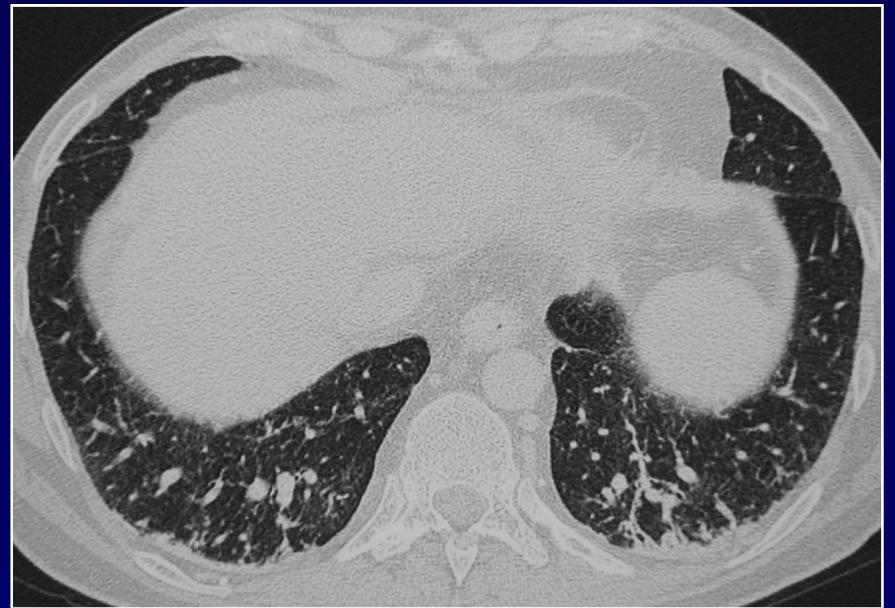

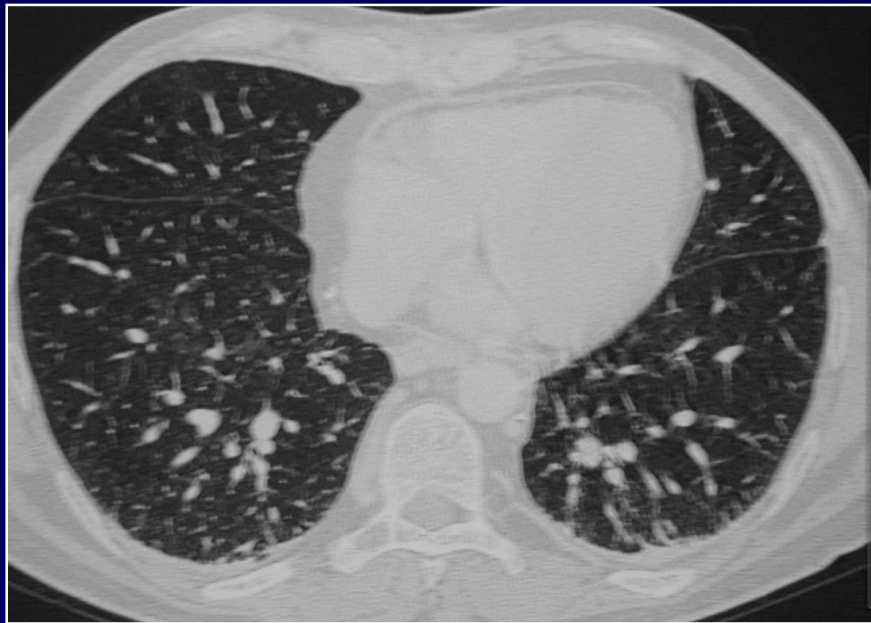
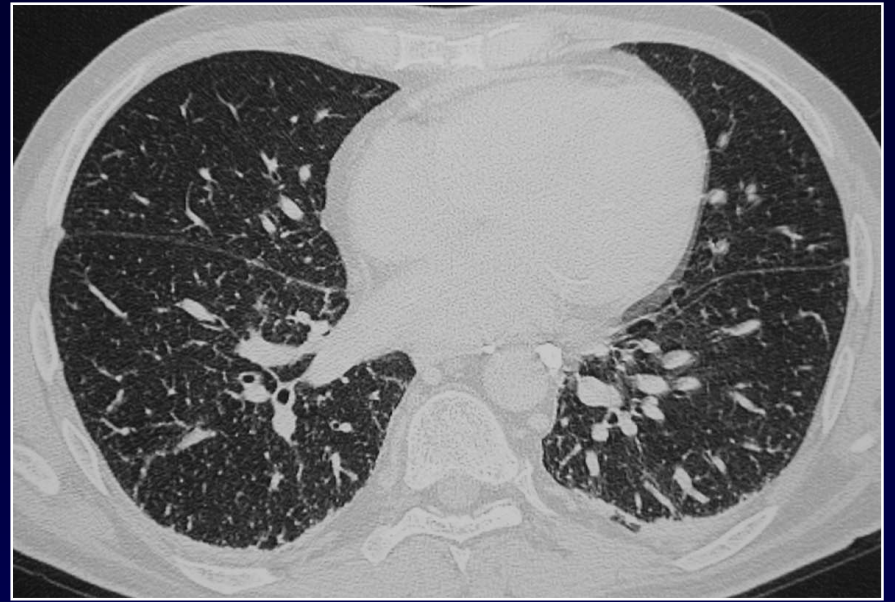
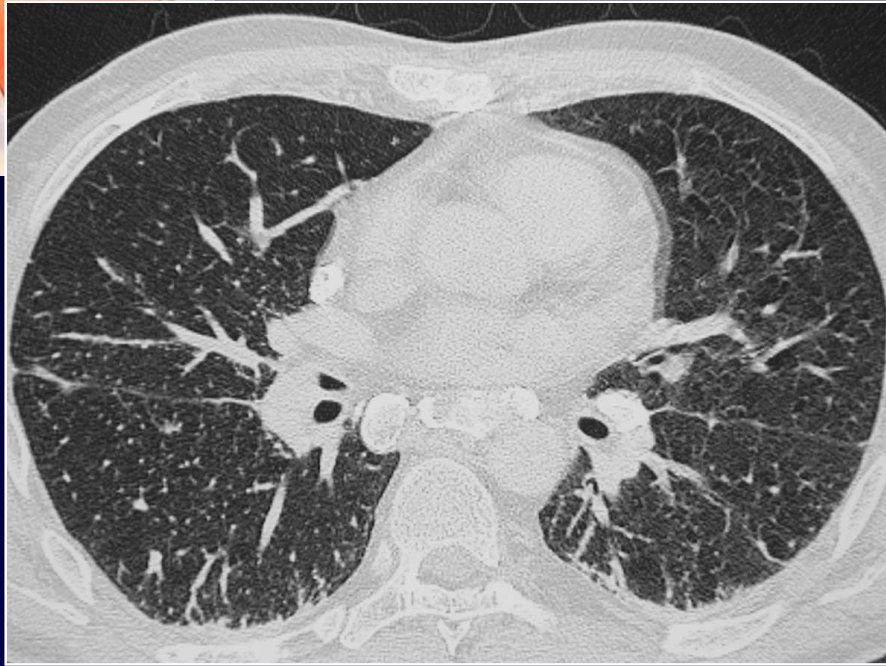


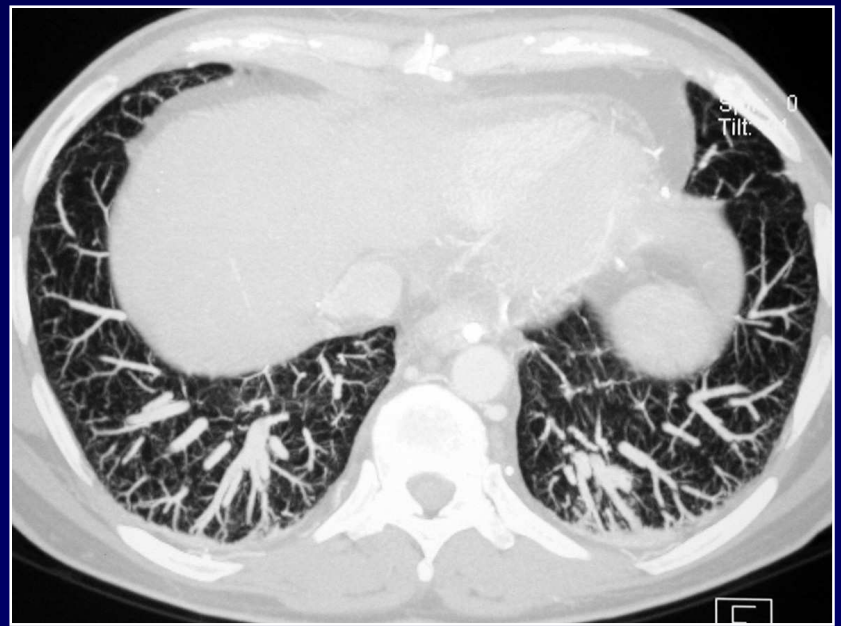
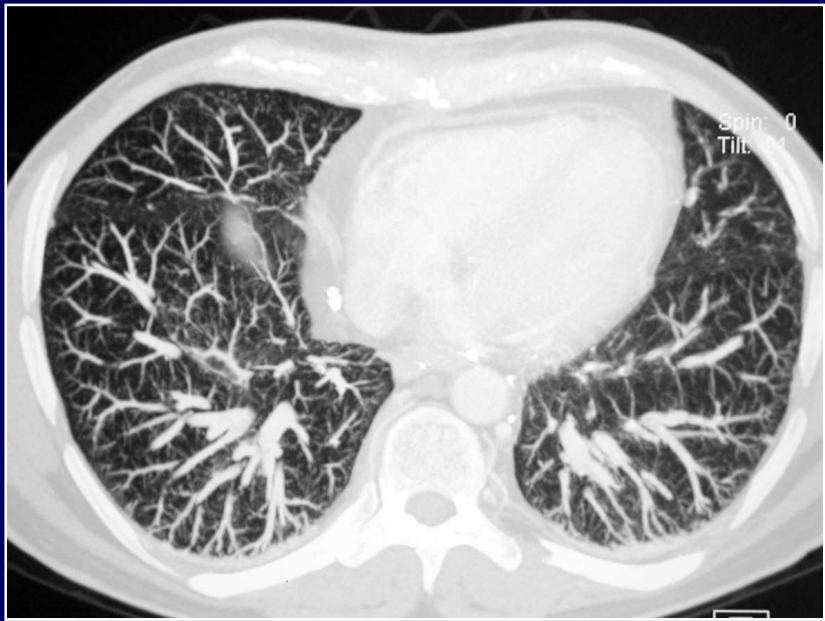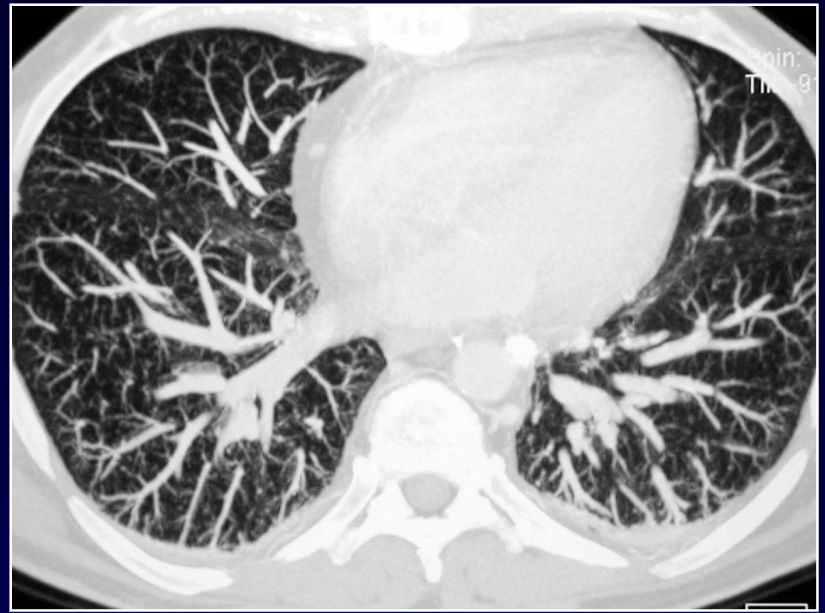
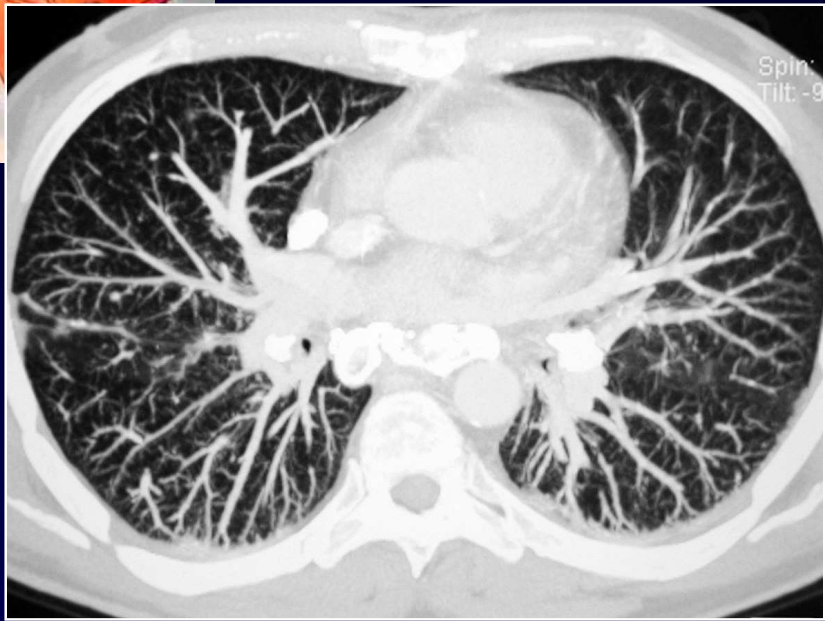
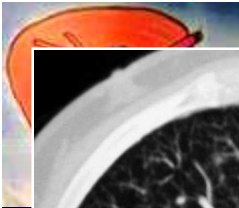
J GIRON

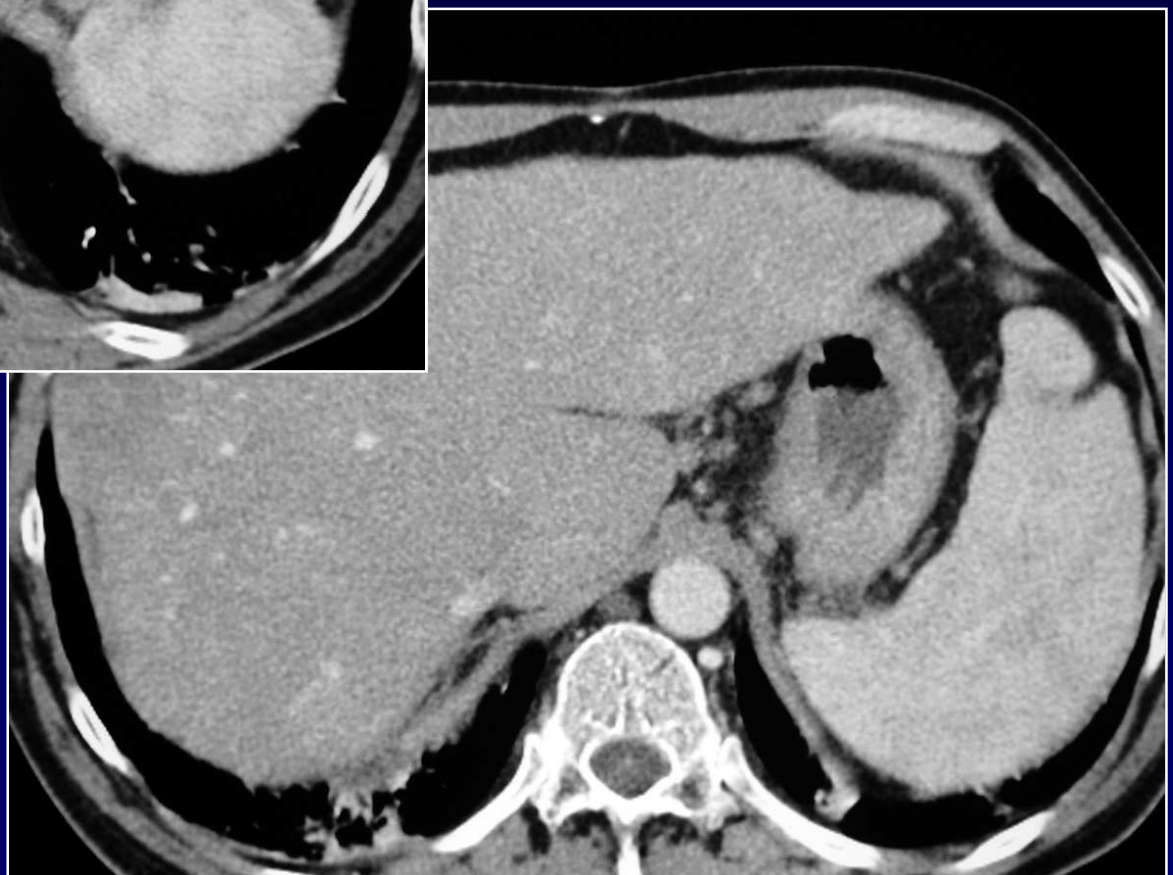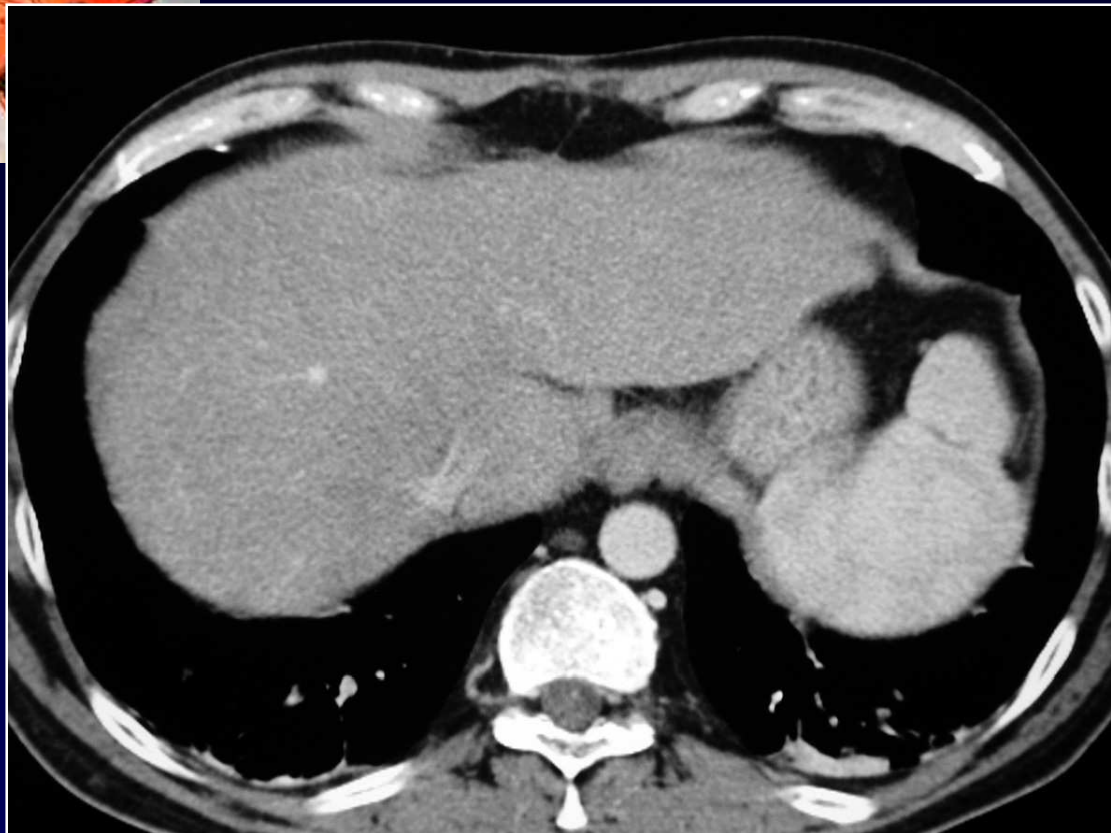
Homme de 52 ans

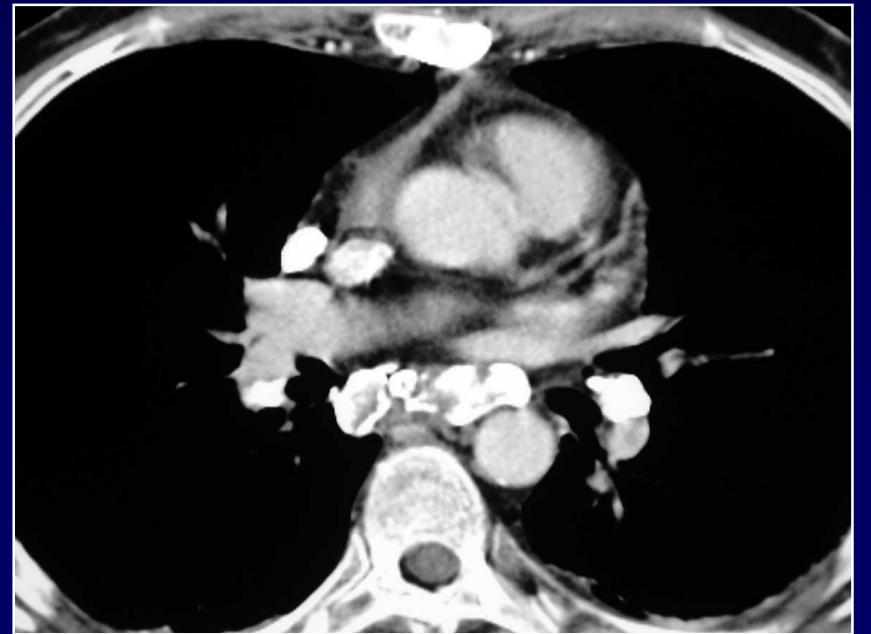
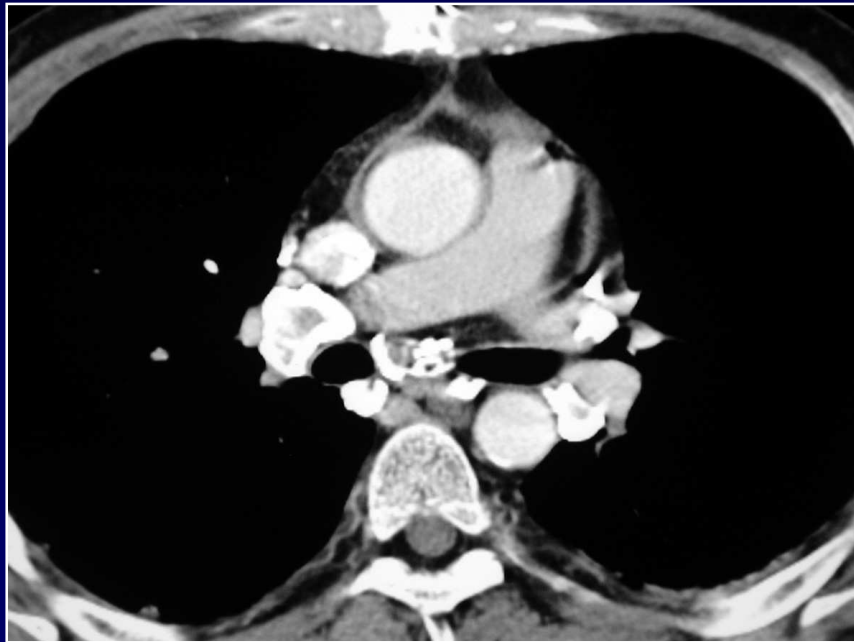
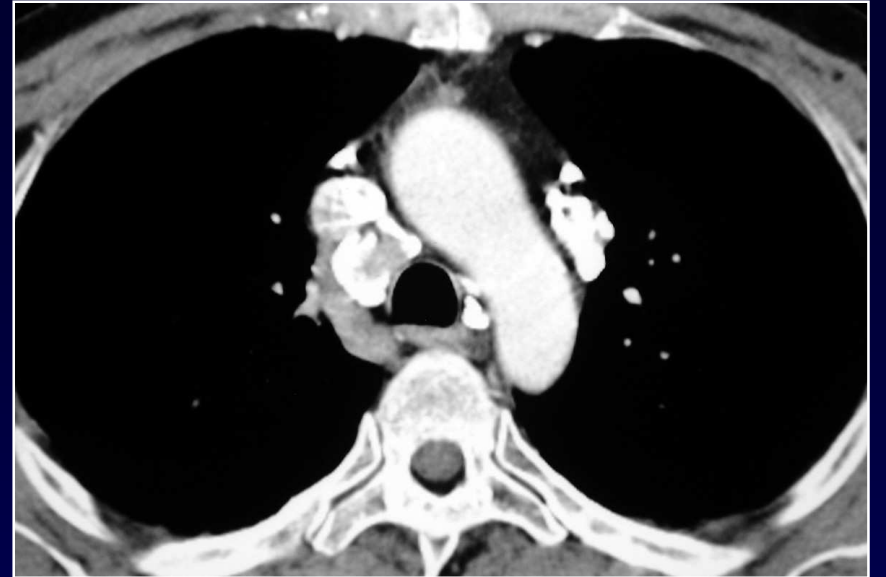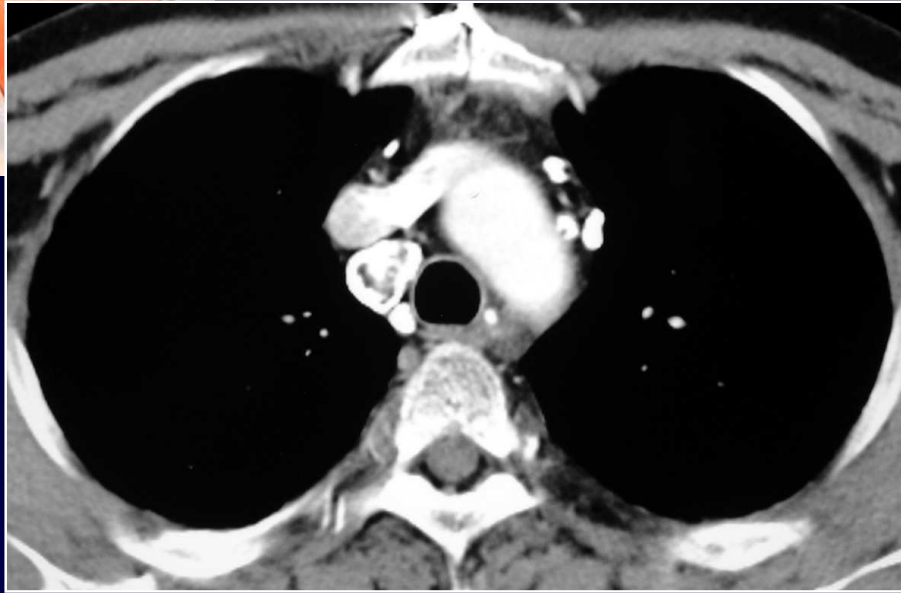
Cirrhose avec HTAP

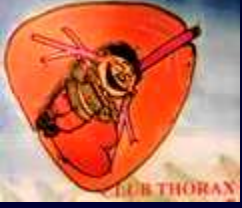Dyspnée avec hypoxie



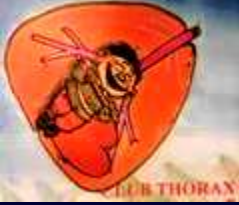







Diagnostic ?



Arguments pour un syndrome hépato-pulmonaire: vaisseaux postérieurs allant jusqu'à la plèvre

L'écho-bulles avait préalablement évoqué le diagnostic

**Adénopathies médiastino-hilaires calcifiées d'origine indéterminée
(antécédents de sarcoïdose?)**